

# Vascular Endothelial Growth Factor A (VEGF-A) and Vascular Endothelial Growth Factor Receptor 2 (VEGFR-2) as Potential Biomarkers for Oral Squamous Cell Carcinoma: A Sri Lankan Study

Sajith Tilal Edirisinghe<sup>1\*</sup>, Manjula Weerasekera<sup>1</sup>, Dulmini Kavindya De Silva<sup>2</sup>, Movini Thisara Devmini<sup>1</sup>, Shanaka Pathmaperuma<sup>1</sup>, Gayan Kanchana Wijesinghe<sup>1</sup>, Thilini Nisansala<sup>1,3</sup>, Anuradha Maddumage<sup>1</sup>, Haizal Huzaini<sup>4</sup>, Allison M Rich<sup>5</sup>, Harsha De Silva<sup>5</sup>, Milne Trudy<sup>6</sup>, Renuka Goonesinghe<sup>7</sup>, Kanishka De Silva<sup>7</sup>, Surangi Yasawardene<sup>1</sup>

## Abstract

**Background:** The incidence of oral squamous cell carcinoma (OSCC) is very high in South Asia and Vascular endothelial growth factor (VEGF) is one of the key factors essential for cancer growth. The importance of VEGF-A and VEGF Receptor 2(VEGFR-2) in oral cancer pathophysiology is yet to be decided. Vascular Endothelial Growth Factor A (VEGF-A) is the main factor concerned in angiogenesis in tumors, but its role in Oral Squamous Cell Carcinoma (OSCC) is still debatable. Our study aimed to determine the role of VEGF-A and VEGFR-2 in OSCC. **Methods:** Blood specimens from 30 patients with primary OSCC and 1:1 age-sex-matched controls were subjected to qPCR and ELISA to detect VEGF-A gene expression and serum level. Tumors of the 30 patients were investigated for VEGF Receptor-2 (VEGFR-2) expression and were analyzed using Image J software version 1.52 for DAB percentage (DAB-P) area and optical density (OD). **Results:** VEGF-A relative gene expression among patients was 2.43-fold higher compared to the healthy control group. Well-differentiated tumors had a 1.98-fold increment, of VEGF gene expression, while poorly differentiated had a 3.58-fold increment. Serum VEGF-A was significantly elevated among the patients compared to controls (458.7 vs 253.2,  $p=0.0225$ ). Patients with poorly differentiated tumors had a higher serum VEGF concentration (1262.0 $\pm$ 354.7pg/ml) compared with other two. Mean VEGFR-2 DAB-P level in OSCC was 42.41 $\pm$ 5.61( $p=0.15$ ). Well-differentiated tumors had a DAB-P of 41.20 $\pm$ 5.32 while poorly differentiated had DAB-P 46.21 $\pm$ 3.78. The mean OD in OSCC was 0.54 $\pm$ 0.16. VEGFR-2 OD in well and poorly differentiated OSCC were 0.48 $\pm$ 0.12 and 0.68 $\pm$ 0.17, respectively. **Conclusions:** VEGF-A gene expression, serum levels, and tissue VEGFR-2 levels correlated linearly with the stage and grade of the tumor. This study justifies the value of VEGF-A as a potential biomarker in OSCC in early detection of OSCC. More studies are needed to accept the use of VEGF-A.

**Keywords:** Vascular endothelial growth factor A- vascular endothelial growth factor receptor-2

*Asian Pac J Cancer Prev*, 24 (1), 267-274

## Introduction

The incidence of oral squamous cell carcinoma (OSCC) is very high in South Asian countries including Sri Lanka. The economic burden associated with the disease is high resulting in a negative impact on the development of the country. In South East Asia, oral cancers account

for 9.3% of mortality among all cancers in both genders (Jayasinghe et al., 2016). Despite the advances in the treatment of OSCC in recent years, the overall survival rate of OSCC is not on the rise. This could probably be due to the lack of an efficient tumor marker for early diagnosis and prediction of the progression and prognosis of OSCC. Despite the various mechanisms involved in

<sup>1</sup>Faculty of Medical Sciences, University of Sri Jayewardenepura, Gangodawila, Nugegoda, Sri Lanka. <sup>2</sup>Department of Anatomy, Faculty of Medical Sciences, University of Sri Jayewardenepura, Gangodawila, Nugegoda Sri Lanka. <sup>3</sup>Faculty of Veterinary Medicine, Universiti Malaysia Kelantan, Pengkalan Chepa, Kota Baru, Kelantan, Malaysia. <sup>4</sup>Sir John Walsh Research Institute, New Zealand. <sup>5</sup>Department of Oral Diagnostic and Surgical Sciences, Faculty of Dentistry, University of Otago, Dunedin, New Zealand. <sup>6</sup>University of Otago, Dunedin, New Zealand. <sup>7</sup>National Cancer Institute of Sri Lanka, Maharagama, Sri Lanka.

\*For Correspondence: edirisinghe@sjp.ac.lk

tumor growth and regulation, angiogenesis (i.e., The growth of new blood vessels from pre-existing ones) plays an important role in tumor growth and metastasis. Vascular endothelial growth factor (VEGF) is one of the key angiogenic proteins produced by tumors to promote angiogenesis which is essential for cancer growth and metastasis (Leek et al., 2000). VEGF can increase vascular permeability, promote endothelial cell proliferation and migration and inhibit endothelial cell apoptosis (Mohamed et al., 2004). Overexpression of VEGF mRNA or protein has been associated with aggressive progression and poor prognosis in several cancers, including colorectal (Deng et al., 2009), gastric (Takahashi et al., 1996), (Yu et al., 2003), pancreatic (Ikeda et al., 1999), and breast carcinomas (Berns et al., 2003). VEGF protein or mRNA may also be a good marker for the prediction of oral cancer progression and prognosis. However, the specific role, if any, of VEGF-A in oral cancer pathophysiology is yet to be determined.

Hence, we aimed to (a) evaluate the expression of VEGF mRNA and protein levels in blood as a less invasive specimen in patients with diagnosed active oral cancer lesions and healthy controls, (b) investigate VEGF Receptor-2 (VEGFR-2) expression in the tumor tissues and (c) compare the above findings of VEGF-A expression with histopathological grade of OSCC .

## Materials and Methods

Ethical approval was granted from the Ethics Review Committee, University of Sri Jayewardenepura (29/16) and National Cancer Institute of Sri Lanka. Thirty patients with primary lesions of oral cancer patients were recruited from the National Cancer Institute of Sri Lanka (Apeksha Hospital) and an equal number of age and sex-matched healthy controls were randomly recruited. Informed written consent was obtained from all the participants. Patients were histologically confirmed of having OSCC and the stage and the grade of the tumors were identified by a consultant histopathologist.

Only patients classified under ICD-O-3 site codes: 00 to 06, were included in this study. Descriptive statistics were analyzed for all continuous variables and the t-tests done were two sided.

### *VEGF-A Quantitative Real-Time PCR*

#### *RNA extraction and cDNA synthesis*

Total RNA was extracted using Invitrogen™ PureLink™ RNA Mini Kit (Applied Biosystems - Thermo Fisher Scientific, Waltham, Massachusetts, USA) and quantified using NanoDrop spectrophotometer (Thermo Fisher Scientific). All the samples were diluted for 60 ng/μl using DEPC-Treated nuclease-free water and subjected to cDNA synthesis using parameters: 20μl of the reactant was reacted for 10 minutes at 25°C, and the reverse transcriptase was inactivated for 5 minutes at 85°C.

#### *Finding the best housekeeping gene*

cDNA of 2 cases and 1 control selected randomly were used to detect the best housekeeping gene. TaqMan™

Array Human Endogenous Control plate (Standard) which consists of 32 housekeeping genes was used. The cycle threshold (Ct) values were entered to the NormFinder software to find out the best stability value. The software suggested the glyceraldehyde-3-phosphate dehydrogenase (GAPDH), Hypoxanthine phosphoribosyltransferase 1 (HPRT1) and Ribosomal protein L30 (RPL30) as the best housekeeping genes. Majority of the OSCC related studies in the literature have used GAPDH as the reference gene. Therefore, GAPDH was selected as the reference gene.

### *Quantitative real-time PCR – VEGF-A*

In the qPCR, the gene expression was assessed as relative quantification. GAPDH (ThermoFisher Scientific) was selected as the control gene (Kim et al., 2015).

Each sample was subjected to real-time PCR in duplicate. The stored cDNA (100 ng/20 μl) was diluted with DEPC-Treated nuclease-free water to achieve 2ng/μl. Then 9μl (18ng) of relevant cDNA samples were inserted into each well and master mixture with Nuclease-Free Water was added to make the final volume per well to 20μl. Thermal cycle conditions consisted of polymerase activation for 10 minutes at 95°C, followed by denaturation for 15 seconds at 95°C. Fluorescence was detected after a final extension of 50 cycles at 60 seconds at 60°C. Patients' VEGF-A gene expression levels were compared with the VEGF-A gene expression of the control group. The fold difference/relative VEGF-A gene expression was calculated using Livak's /  $\Delta\Delta Ct$  method.  $\Delta Ct (\Delta Ct)$  is the difference of average Ct of target gene (VEGF gene) and housekeeping gene (GAPDH). Using this formula, the difference of mean Ct values of controls and cases was determined, which is double delta Ct ( $\Delta\Delta Ct$ ) =  $\Delta Ct$  Controls –  $\Delta Ct$  Cases. Fold change (FC) compares the expression of genes between cases and controls by the following:  $FC = 2^{\Delta\Delta Ct}$

Primers and probes used in the study are mentioned in Table 1.

### *VEGF-A protein levels in patients' serum*

#### *VEGF-A ELISA*

Serum VEGF-A concentration of blood was measured using ELISA (Abcam, UK) according to the manufacturer's instructions. The detection range of the assay was 0–1000pg/ml and the standard curve for the assay was generated following manufacturer's instructions. Serum specimens for ELISA were diluted by half and all standards and specimens were carried out in duplicate. The GraphPad Prism 6 (GraphPad Software Inc.) was used to determine the levels of VEGF-A and for statistical analysis.

### *Immunohistochemistry (IHC) staining for the detection of VEGFR-2 in the tumor*

A normal tongue tissue from a fresh deceased person and an umbilical cord were used as the reference tissues. The tissues were fixed in 10% formalin for 6-12 hours. The selected tissues were placed in cassettes and labeled. The cassettes were loaded onto an automated tissue processor for processing according to standard protocols. After processing, the specimens were embedded in a solid wax

Table 1. Targeted Genes, Primer Sequences and Probes Used in the Study.

Gene	Primer/ probe sequence	Reference
VEGF forward primer	5'-GCACCCATGGCAGAAGG-3'	
VEGF reverse primer	5'-CTCGATTGGATGGCAGTAGCT-3'	
VEGF probe	5'-FAM-ACGAAGTGGTGAAGTTCATGGATGTCTATCAC-TMARA-3'	(Kim et al., 2015)
GAPDH forward primer	5'-GAAGGTGAAGGTCGGAGTC-3'	
GAPDH reverse primer	5'-GAAGATGGTGTATGGGATTTC-3'	
GAPDH probe	5'-FAM-CAAGCTTCCCGTTCTCAGCCTAMRA-3'	

block to obtain thin tissue sections for histology slide preparation.

Thick tissue sections (4µm) were obtained from the normal tongue of a deceased person, umbilical cords (reference tissues) and tumors using a microtome. Two slides were prepared from each wax block. One was for IHC and one for the Haematoxylin and Eosin (H & E) staining. Tissue sections were transferred onto labeled poly-L-Lysine coated charged slides for IHC (Eberle et al., 2010) and normal microscope slides for H & E staining (Feldman and Wolfe, 2014).

The slides were initially dipped in two baths of xylene and absolute ethanol for 5 min each. Then the slides were rehydrated using descending concentrations of ethanol (90% and 70%) for 5 minutes. Antigen retrieval was performed before commencing with immunostaining. Immunostaining was done using primary (ab9530) and secondary (ab205719) antibodies according to manufacture protocol (Abcam, UK).

Images of all immunostained slides were photographed using the Dino-Eye Eyepiece Camera attached to the CX 30 Olympus microscope and subjected to the Image J software version 1.52, and the optical density (OD) and diaminobenzidine (DAB) expression percentage measurements were calculated (Crowe and Yue, 2019).

## Results

Out of the 30 OSCC patients, 22 were males while 8 were females. Sixty percent of the patients (18/30) had well-differentiated OSCC, while 26.6% (08/30) had moderately differentiated OSCC and 13.3% (04/30) had poorly differentiated OSCC.

The majority [60% (18/30)] had cancers on their tongue. 30 percent (09/30) of tissues belonged to buccal mucosal sites and 10% (03/30) to other mucosal sites (ICD-0-3, site codes: 00 to 06).

### VEGF-A gene expression levels

The relative expression of VEGF-A gene of the patients compared to controls ranged from 1.04-3.94. OSCC patients had a significantly higher level of VEGF-A gene expression (2.43±0.80-fold higher) compared to the matched healthy controls. The 18 patients with well-differentiated OSCC had a 1.98-fold increase of VEGF-A expression while moderately differentiated OSCC patients had a 2.89-fold increase.

Out of the 30 patients, 25 had stage I and stage II tumours. Their VEGF-A expression mean fold increase was 2.27±0.74. A total of 05/30 patients had stage III and IV tumours and their mean VEGF-A expression value was 3.27±0.55 folds. The mean value difference of VEGF A gene expression was statistically significant(p=<0.0001).

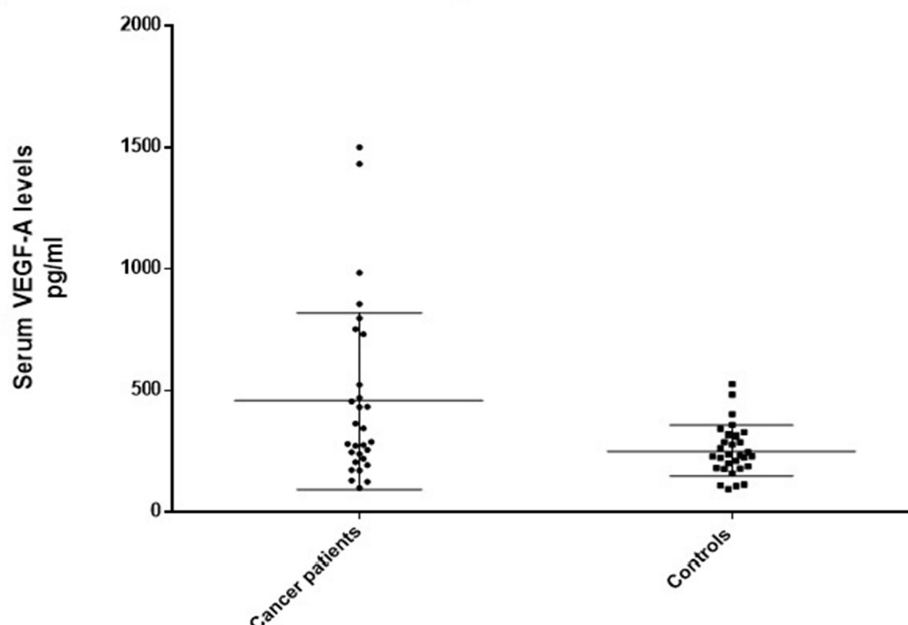


Figure 1. Serum VEGF-A Concentrations among OSCC Patients and Healthy Controls

Table 2. The Summary of the *VEGF-A* Gene Expression in Blood, VEGF-A Serum Concentrations and *VEGFR-2* Expression in the Tissues

Clinical and pathological characteristics	Actual N (%)	VEGF-A gene expression Fold increase	VEGF-A serum concentrations		VEGFR-2 tissue expression			
			pg/ml Patients	pg/ml Controls	DAB %		OD levels	
					Patients	Controls	Patients	Controls
Overall average	30	2.43±0.80 (P<0.000)	458.7±253.2	253.2±102.5 (p=0.0043)	42.41±5.61	38.04±2.21	0.54±0.16	0.31±0.007
Gender								
Male	22	2.56 ±0.79	483.22±07.32	256.94±96.75	42.60±5.30	37.34±2.62	0.56±0.16	0.318±0.009
Female	8	2.09±0.76	334.02±209.44	243.01±123.64	41.8±6.76	39.4	0.49±0.14	0.315
Clinical and pathological characteristics	Actual N (%)	VEGF-A gene expression Fold increase	VEGF-A serum concentrations		VEGFR-2 tissue expression			
			pg/ml Patients		DAB % Patients		OD levels Patients	
Clinical Stage								
I-II	25 (0.83)	2.27±0.74 (1.04-3.59)	383.85±252.86		41.99±5.18		0.52±0.14	
III-IV	05 (0.16)	3.27±0.55 (1.04-3.59)	741.33±680.97		44.49±7.78		0.67±0.22	
Tumour size								
T1-T2	25 (0.83)	2.27±0.74	383.85±252.86		41.99±5.18		0.52±0.14	
T3-T4	05 (0.16)	3.27±0.55	741.33±680.97		44.49±7.78		0.67±0.22	
Clinical and pathological characteristics	Actual N (%)	VEGF-A gene expression Fold increase	VEGF-A serum concentrations		VEGFR-2 tissue expression			
			pg/ml Patients		DAB % Patients		OD levels Patients	
Nodal involvement								
Absent (N0)	26 (0.86)	2.32±0.77	444.17±323.21		42.08±5.10		0.529±0.14	
Present (N+)	04 (0.13)	3.18±0.59	568.93±648.19		44.55±8.98		0.67±0.25	
Distant metastasis								
No distant metastasis (M0)	28 (0.93)	2.38±0.80	409.28±319.86		42.02±5.61		0.53±0.15	
Distant metastasis (M+)	02 (0.06)	3.16±0.003	921.53±818.27		47.76±1.55		0.76±0.01	
Clinical and pathological characteristics	Actual N (%)	VEGF-A gene expression Fold increase	VEGF-A serum concentrations		VEGFR-2 tissue expression			
			pg/ml Patients		DAB % Patients		OD levels Patients	
Histological Grade								
Well differentiated	18 (0.60)	1.98±0.64	279.5±162.4		41.20±5.32		0.48±0.12	
Moderately differentiated	08 (0.26)	2.89±0.32	560.8±245.7		43.21±6.48		0.61±0.18	
Poorly differentiated	04 (0.13)	3.58±0.32	1262.0±354.7		46.21±3.78		0.68±0.17	
Clinical and pathological characteristics	Actual N (%)	VEGF-A gene expression Fold increase	VEGF-A serum concentrations		VEGFR-2 tissue expression			
Unit			pg/ml Patients		DAB % Patients		OD levels Patients	
Site of the lesion								
Tongue	18 (0.60)	2.41±0.50	448.56±327		42.30±4.30		0.55±0.12	
Buccal Mucosa	09 (0.30)	2.18±1.18	383.44±469.89		39.27±6.08		0.46±0.19	
Other Mucosal sites	03 (0.10)	3.38±0.14	592.68±340.46		50.37±3.34		0.74±0.11	

The VEGF-A gene expression increased with the increase of tumour size and nodal involvement. Tumours with T1/T2 size had a mean value of 2.27-fold increase of the VEGF-A gene expression (Table 2).

#### Serum VEGF-A levels

Mean VEGF-A level in serum of patients with OSCC was 458.7±253.2pg/ml (range 101.63-1500.14pg/ml) whereas mean VEGF-A level in healthy controls was found to be 253.2±102.5pg/ml (range 96.19-526.76pg/ml) (Figure 1). The mean VEGF-A level in patients with OSCC was significantly higher than in healthy controls

(p=0.0225).

Patients with stage I-II of the OSCC had a mean VEGF-A level of 383.85±252.86pg/ml while stage III-IV of OSCC patients had a mean VEGF-A value of 926.66±623.95pg/ml (p=0.0036). Tumours with T1/T2 size had a serum VEGF-A mean value of 423.89±307.95pg/ml, and T3/T4 tumour size had a mean value of 676.43±638.34pg/ml. The tumours with lymph node metastasis had a serum VEGF-A value of 528.59±567.05pg/ml (Table 2).

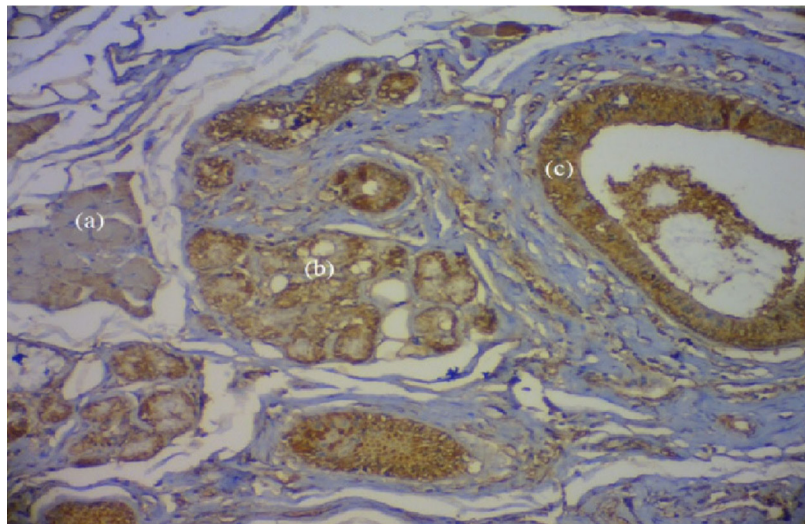


Figure 2. VEGFR-2 expression on Normal Tissue (a) muscle fibers, (b) Salivary gland, (c) Blood vessel

#### Tissue VEGFR-2 expression

The tumour tissues of the 30 patients were subjected to IHC analysis. The images of all the slides were photographed using the Dino-Eye Eyepiece camera attached to the CX 30 Olympus microscope at x40 and x100 magnifications. In normal tissue VEGFR-2 was positive in vascular endothelium, salivary glands and skeletal muscle with varying intensity. The signal was relatively weak in the skeletal muscle fibres (Figure 2).

#### Optical Density (OD)

The immunostaining intensity of the tumour tissue was quantified using digital computer-assisted analysis. Mean VEGFR-2 OD level in tissues of patients with OSCC was  $0.54 \pm 0.16$  (range 0.29-0.87) while in controls it was  $0.31 \pm 0.007$  (range 0.31-0.32). The mean OD of VEGFR-2 level in the tissues of patients with OSCC was not significantly higher than that in healthy controls ( $p=0.15$ ).

When considering the tumour stage, I/II of the OSCC had a mean value of  $0.52 \pm 0.14$ , while stage III/IV of OSCC had  $0.67 \pm 0.22$ . In patients with well-differentiated OSCC ( $n=18$ ), while the OD level of poorly differentiated OSCC ( $n=04$ ) the mean value was  $0.68 \pm 0.17$ . Tongue squamous cell carcinoma (SCC) had an OD value of  $0.55 \pm 0.12$  (0.29-0.77 (Table 2).

In tumour tissues, VEGFR-2 staining showed mixed, membranous and cytoplasmic staining (Figure 2). The

well-differentiated tumours (a) showed both membranous and cytoplasmic staining and similar appearance was noted in the moderately differentiated tumours (b). But poorly differentiated tumours (c) showed more homogenous stains throughout the tumour and more cytoplasmic expression instead of membrane expression.

#### DAB percentage

Mean VEGFR-2 percentage level in tissues of patients with OSCC was  $42.41 \pm 5.61$  (range 31.39-53.79%), while control tissues had VEGFR-2 levels of  $38.04 \pm 2.21$  (range 35.48-39.44). The mean VEGFR-2 level in the tissues of patients with OSCC was not significantly higher than that in healthy controls ( $p=0.15$ ) (Table 2).

## Discussion

Our study evaluated the serum VEGF-A gene expression, its serum concentrations and VEGFR-2 expression on tumour tissue. Angiogenesis is a crucial requirement for tumour growth, infiltration, and metastasis (Kerbel, 2000). Although early-stage tumours are relatively avascular, when the tumours become larger than 1 to 2mm, fibroblasts around tumour cells secrete substances that stimulate angiogenesis and infiltrate the tumour. The proliferated micro-vessels supply nutrients to tumour cells. The vascular endothelial cells secrete growth factors such as basic fibroblast growth factor

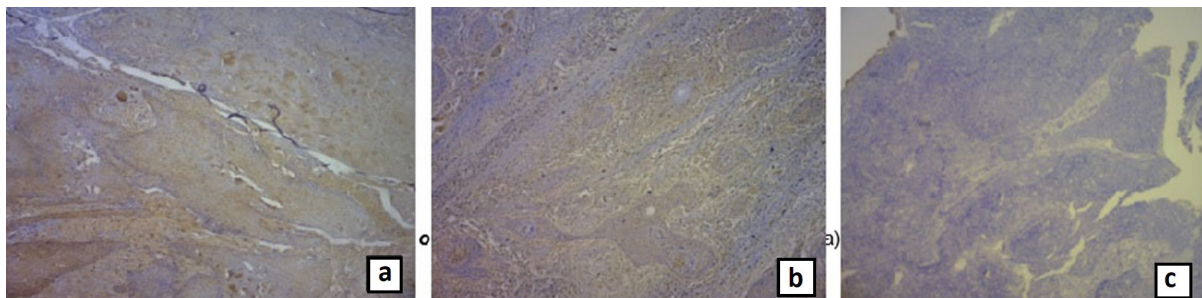


Figure 3. Immunohistochemical Staining of Oral Carcinoma. Well-differentiated tumour(a), moderately differentiated tumour(b) and poorly differentiated tumour(c) (x 40)

(bFGF), insulin-like growth factor-2, and vascular endothelial growth factors (VEGF) to help tumour growth. The function of VEGF in cancer is not only limited to angiogenesis and vascular permeability. VEGF-mediated signalling occurs in tumour cells which leads to key aspects of tumorigenesis.

In our study a significant elevation of VEGF-A mRNA and serum protein expression was observed. The study included 30 patients with OSCC and an equal number of age $\pm$ 5 years and gender-matched controls. As a significant finding of the current study, a 2.43-fold increase in the mean VEGF-A relative quantification was seen among the patients compared to the control group.

Many studies have reported that VEGF expression increases micro-blood vessel density in tumours of the colon, ovary, liver, gastrointestinal tract, kidney, breast and head and neck regions, and that those tumour cells express VEGF mRNA and secrete VEGF-like proteins (Volm et al., 1997). Therefore, VEGF is considered to have an important role in human cancer. However, its diagnostic value has not been widely accepted because the conclusions are inconsistent and even conflicting.

A study conducted in India by Aggarwal et al. has shown the mRNA expression levels of VEGF to be approximately 7-fold higher in tumours as compared to the normal area of the same tissue (Aggarwal et al., 2014). The higher expression level seen in published studies compared to the present study may be due to the difference in the type and location of tissues used in those studies. In Aggarwal's study, they have used the tumour tissues, whereas in the present study, blood from the peripheral veins was used. The reason to select blood is that it is convenient and less invasive to obtain samples for investigations (Aggarwal et al., 2014). There is an ongoing debate in data to prove what the best sample is (blood vs. cancer tissue) for gene expression studies. A study conducted by Kim et al. has highlighted a strong relationship between VEGF mRNA expression (average 2.26) and OSCC in all 20 oral squamous cell carcinoma tissue (Kim et al., 2015).

An Indian study has shown that the measurement of VEGF mRNA expression in oral cancer tissues by real-time PCR is a more sensitive technique than the detection of VEGF by ELISA and expression of VEGFR by IHC (Aggarwal et al., 2014). In the present study, both real-time PCR and ELISA were used to determine the VEGF-A expression levels in the blood. A similar study conducted by Sales et al. in Brazil showed that the VEGF expression in OSCC is 17-fold greater compared to the normal population (Sales et al., 2016).

VEGF-induced angiogenesis is an essential factor for tumour growth and metastasis (Ferrara et al., 1991). Our study demonstrated an association, an increase of VEGF gene expression in OSCC patients with increased tumour size (T3-T4) and positive lymph node metastasis (N+). A study conducted in Taiwan has demonstrated a positive correlation between VEGF expression in OSCC tissues and positive regional lymph node metastasis (Ko et al., 2015; Cheng et al., 2011). Higher T and N statuses indicate an advanced clinical stage. OSCC patients with a higher expression of VEGF mRNA are prone to have

more advanced clinical staging. Higher VEGF protein expression is related not only to OSCC but also to more advanced clinical stages of colon and gastric carcinomas as well (Yu et al., 2003; Takahashi et al., 1995). A positive relationship between overexpression of VEGF protein or mRNA in cancer tissues and lymph node metastasis has also been reported in head and neck SCC (Mineta et al., 2000).

As VEGF gene expression was increased in advanced OSCC, tumours with lymph node metastasis, it was noted that it is worth investigating the serum VEGF-A levels in OSCC to predict the invasiveness and metastasis. The present study highlights the quantitative data on the concentration of serum VEGF-A and its expression in tumour tissue in 29 patients with OSCC (1 sample removed due to outlying) and 30 healthy controls. The results showed that the mean VEGF-A level in the serum of patients with OSCC was significantly higher than that in healthy controls. Studies conducted by Shang et al. in 2002 in China and Nayak et al., (2012) in India have reported similar findings. The serum VEGF levels increase with the stage of the tumour. Also, they highlight that the poor differentiation of the tumour tissue is related to higher serum VEGF-A levels. The Indian study has compared the serum levels of VEGF-A in OSCC (1264.08 $\pm$ 1216.70 pg/ml) with premalignant oral lesions (462.54 $\pm$ 344.76 pg/ml) and controls (187.91 $\pm$ 106.75 pg/ml). It highlights that VEGF-A levels of OSCC patients were comparatively higher than the normal, and results were comparable with the present study.

Since the sample size is small in the present study, before serum VEGF-A can be translated into a practical biomarker, it requires well-controlled large-scale, multicentre studies in different geographical locations, and clinical-epidemiological, aetiological factors and follow up studies for serum VEGF expression in post-treatment cases (Qian et al., 2000).

It is a widely accepted phenomenon that angiogenesis is an essential event in tumour progression. In the development of a solid tumour, the cell population depends on the availability and the balance between pro-angiogenic and anti-angiogenic factors (Johnstone and Logan, 2007; Mărgăritescu et al., 2010). It is important to investigate the expression of VEGFR-2 receptors in the tumour tissue of OSCC. There are also published results showing the expression of VEGFR-2 in the tumour cells in addition to VEGFs in head and neck squamous cell carcinomas (HNSCC) (Kyzas et al., 2005). VEGFR-2 is identified in normal tissues such as the canalicular epithelium of salivary glands, hair follicles, sebaceous glands and striated muscle fibers. We noted a positive immunohistochemical reaction for VEGFR-2 on tumour cells. Similarly, in literature, studies have reported positive staining of VEGFR-2 on tumour cells of OSCC (Kyzas et al., 2005). But in some studies, expression of VEGFR-2 was not found on tumour cells of OSCC and in some, VEGFR-2 staining had been confined to isolated cells in the stroma (Sato and Takeda, 2009). The conclusion drawn by the researchers was that the presence of the VEGF receptors on OSCC tumour cells suggests that they are involved in an autocrine regulatory loop initiated and

centered around the VEGF family (Kyzas et al., 2005). There are very limited data in the literature analysing the correlations between VEGFR-2 receptors and clinical and pathological characteristics such as tumour size, grade or stage in OSCC. The present study demonstrates variations of VEGFR-2 with tumour size, grade and stage in OSCC. In the present study, we also found that the males expressed VEGFR-2 more than females (Table 2). With the advancement of the grade of cancer, the VEGFR-2 OD and DAB percentage increased. The well-differentiated tumours had a lower OD and lower DAB percentage reflecting lower VEGFR-2 expression, and poorly differentiated tumours had higher OD and DAB percentage values reflecting high VEGFR-2 receptors. Similarly, Sato and Takeda have shown that the VEGFR-2 expression was higher in poorly differentiated OSCC than in well-differentiated OSCC (Sato and Takeda, 2009). When considering the tumour stage, the present study showed an increase of OD and DAB percentage with the stage. Tumours with nodal metastases had a greater value compared to tumours without nodal involvement.

A study by Stinga et al., (2011) revealed that lymph node involvement-positive tumours showed higher expression of VEGFR-2 compared to non-nodal involved tumours. Certain studies have reported opposite results, demonstrating that VEGF expression levels were increased in the normal mucosal epithelium and in the early stage of premalignant lesions compared to later stages of head and neck cancers (Tae et al., 2000). A study conducted on VEGFR-2 expression in breast cancers has also shown a similar pattern to the present study. In that study, the breast carcinoma tissues had a high expression level of VEGFR-2 with a lymph node-positive status and poor prognosis. The author has shown that VEGFR-2 expression is correlated with high metastasis (Yan et al., 2015).

An elevation was noticed in VEGF-A gene expression, serum level, and VEGFR-2 expression with the stage and the grade of the tumor. This study justifies the value of VEGF-A as a potential early biomarker in OSCC. More studies are needed to accept the use of VEGF-A in the prediction, diagnosis and evaluation of OSCC.

## Author Contribution Statement

All authors listed have made a substantial, direct, and intellectual contribution to the work, and approved it for publication.

## Acknowledgments

The patients and normal subjects who volunteered for the study by providing blood and tissue samples and the laboratory technicians at the Department of Anatomy and Microbiology, Faculty of Medical Sciences, University of Sri Jayewardenepura, Dental School, University of Otago, New Zealand and at the Pathology laboratory, National Cancer Institute of Sri Lanka.

## Funding

This work was supported by the University of Sri Jayewardenepura [grant numbers ASP/01/RE/

MED/2016/46 and ASP/01/RE/MED/2017/62]; and the Center for Cancer Research of University of Sri Jayewardenepura [grant number 003/17].

## Ethical clearance

Ethical approval was granted from the Ethics Review Committee, University of Sri Jayewardenepura (29/16), National Cancer Institute of Sri Lanka (Apeksha Hospital).

## Data Availability

Data will be made available freely to any interested parties upon publication of the article. For further information clarification please contact the corresponding author.

## Conflicts of Interest

There are no conflicts of interest.

## References

- Aggarwal S, Devaraja K, Sharma SC, Das SN (2014). Expression of vascular endothelial growth factor (VEGF) in patients with oral squamous cell carcinoma and its clinical significance. *Clin Chim Acta*, **436**, 35-40.
- Berns EM, Klijn JG, Look MP, et al (2003) Combined vascular endothelial growth factor and TP53 status predicts poor response to tamoxifen therapy in estrogen receptor-positive advanced breast cancer. *Clin Cancer Res*, **9**, 1253-8.
- Cheng SJ, Lee JJ, Kok SH, et al (2011). Expression of vascular endothelial growth factor is significantly associated with progression and prognosis of oral squamous cell carcinomas in Taiwan. *J Formos Med Assoc*, **110**, 50-7.
- Crowe AR, Yue W (2019). Semi-quantitative determination of protein expression using immunohistochemistry staining and analysis: an integrated protocol. *Bio Protoc*, **9**.
- Deng YT, Chen HM, Cheng SJ, Chiang CP, Kuo MYP (2009). Arecoline-stimulated connective tissue growth factor production in human buccal mucosal fibroblasts: Modulation by curcumin. *Oral Oncol*, **45**, e99-e105.
- Eberle FC, Hanson JC, Killian JK, et al (2010). Immunoguided laser assisted microdissection techniques for DNA methylation analysis of archival tissue specimens. *J Mol Diagn*, **12**, 394-401.
- Feldman AT, Wolfe D (2014). Tissue processing and hematoxylin and eosin staining. In 'Histopathology': Springer, Salmon Tower in Midtown Manhattan, New York City. p 31-43.
- Ferrara N, Houck KA, Jakeman LB, Winer J, Leung DW (1991). The vascular endothelial growth factor family of polypeptides. *J Cell Biochem*, **47**, 211-8.
- Ikeda N, Adachi M, Taki T, et al (1999). Prognostic significance of angiogenesis in human pancreatic cancer. *Br J Cancer*, **79**, 1553.
- Jayasinghe R, Sherminie L, Amarasinghe H, Sitheequ M (2016). Level of awareness of oral cancer and oral potentially malignant disorders among medical and dental undergraduates. *CMJ*, **61**.
- Johnstone S, Logan R (2007). Expression of vascular endothelial growth factor (VEGF) in normal oral mucosa, oral dysplasia and oral squamous cell carcinoma. *Int J Oral Maxillofac Surg*, **36**, 263-6.
- Kerbel RS (2000). Tumor angiogenesis: past, present and the near future. *Carcinogenesis*, **21**, 505-15.
- Kim SK, Park SG, Kim KW (2015). Expression of vascular endothelial growth factor in oral squamous cell carcinoma. *J Korean Assoc Oral Maxillofac Surg*, **41**, 11-8.
- Ko HH, Lee JJ, Chen HM, et al (2015). Upregulation of vascular

- endothelial growth factor mRNA level is significantly related to progression and prognosis of oral squamous cell carcinomas. *J Formos Med Assoc*, **114**, 605-11.
- Kyzas PA, Stefanou D, Batistatou A, Agnantis NJ (2005). Potential autocrine function of vascular endothelial growth factor in head and neck cancer via vascular endothelial growth factor receptor-2. *Mod Pathol*, **18**, 485-94.
- Leek RD, Hunt NC, Landers RJ et al (2000). Macrophage infiltration is associated with VEGF and EGFR expression in breast cancer. *J Pathol*, **190**, 430-6.
- Mărgăritescu C, Pirici D, Stîngă A et al (2010). VEGF expression and angiogenesis in oral squamous cell carcinoma: an immunohistochemical and morphometric study. *Clin Exp Med*, **10**, 209-14.
- Mineta H, Miura K, Ogino T, et al (2000). Prognostic value of vascular endothelial growth factor (VEGF) in head and neck squamous cell carcinomas. *Br J Cancer*, **83**, 775-81.
- Mohamed KM, Le A, Duong H, et al (2004). Correlation between VEGF and HIF-1 $\alpha$  expression in human oral squamous cell carcinoma. *Exp Mol Pathol*, **76**, 143-52.
- Nayak S, Goel MM, Chandra S, et al (2012). VEGF-A immunohistochemical and mRNA expression in tissues and its serum levels in potentially malignant oral lesions and oral squamous cell carcinomas. *Oral Oncol*, **48**, 233-9.
- Qian CN, Zhang CQ, Guo X, et al (2000). Elevation of serum vascular endothelial growth factor in male patients with metastatic nasopharyngeal carcinoma. *Cancer*, **88**, 255-61.
- Sales CBS, Buim MEC, de Souza RO et al (2016). Elevated VEGFA mRNA levels in oral squamous cell carcinomas and tumor margins: a preliminary study. *J Oral Pathol*, **45**, 481-5.
- Sato H, Takeda Y (2009). VEGFR2 expression and relationship between tumor neovascularization and histologic characteristics in oral squamous cell carcinoma. *J Oral Sci*, **51**, 551-7.
- Stinga A, Margaritescu O, Stinga AS, et al (2011) VEGFR1 and VEGFR2 immunohistochemical expression in oral squamous cell carcinoma: a morphometric study. *Rom J Morphol Embryol*, **52**, 1269-75.
- Tae K, ElNaggar AK, Yoo E, et al (2000). Expression of vascular endothelial growth factor and microvessel density in head and neck tumorigenesis. *Clin Cancer Res*, **6**, 2821-8.
- Takahashi Y, Cleary KR, Mai M, et al (1996). Significance of vessel count and vascular endothelial growth factor and its receptor (KDR) in intestinal-type gastric cancer. *Clin Cancer Res*, **2**, 1679-84.
- Takahashi Y, Kitadai Y, Bucana CD, et al (1995). Expression of vascular endothelial growth factor and its receptor, KDR, correlates with vascularity, metastasis, and proliferation of human colon cancer. *Cancer Res*, **55**, 3964-8.
- Volm M, Koomägi R, Mattern J (1997). Prognostic value of vascular endothelial growth factor and its receptor Flt-1 in squamous cell lung cancer. *IJC*, **74**, 64-8.
- Yan JD, Liu Y, Zhang ZY, et al (2015). Expression and prognostic significance of VEGFR-2 in breast cancer. *Pathol Res Pract*, **211**, 539-43.
- Yu JX, Zhang XT, Liao YQ, et al (2003). Relationship between expression of CD105 and growth factors in malignant tumors of gastrointestinal tract and its significance. *World J Gastroenterol*, **9**, 2866.



This work is licensed under a Creative Commons Attribution-Non Commercial 4.0 International License.